

"How to Take Dental Radiographs"

14th AAEPV Annual Convention

San Francisco, 2018

Jack Easley DVM, MS, DABVP (Equine), DACVD (Equine)

Introduction

Equine skull radiography to be a valuable tool in the diagnosis and management of sinus and dental disease. The excellent contrast between air, bone, soft tissue, and tooth substance make the head an ideal area for radiographic evaluation. Conventional or standard radiographic projections adequately image the reserve crown apices, lamina dura denta, alveolar space, and alveolar bones as well as changes in the associated maxillary, mandible, and sinonasal structures. With these conventional closed-mouth radiographic projections, the erupted crown is obscured by superimposition of the crowns of the opposite dental arcades.

Until recently, radiography has been of limited value in the assessments of lesions involving the gingival margins or evaluation of the exposed tooth crown. With the introduction of open mouth oblique radiographic views, a more accurate diagnosis of lesions affecting the clinical crowns of the check teeth can be made. With the development of smaller flexible intra-oral equine dental cassettes used with plain film or DR plates, the entire crown and apical region of a tooth can be imaged.

Several factors may limit acquiring good quality films (i.e., size of the horse, types of intensifying screens, and films and exposure capabilities of the portable x-ray machine). Some limitations can be overcome by reducing movement of the horse's head and appropriate positioning of the x-ray cassette and x-ray machine while taking the radiography. The differences in tissue density and the increasing width of the horse's head from rostral to caudal may require more than one radiographic exposure of the anatomical area to highlight the tissues to be evaluated. With DR and CR, the computer algorithms in the radiographic system can be adjusted to compensate for most variations in tissue thickness.

To generate the required image, knowledge of skull anatomy and topographic landmarks is necessary to insure correct positioning of the x-ray unit, cassettes, and horse's head. The head is anatomically complex and the use of large cassettes -12X14" – helps maintain spatial relationships when evaluating the radiograph. Coning down on the radiograph will allow better contrast and detail over a smaller area of greater concern. It is helpful to use both right and left projections to take advantage of image sharpness and magnification in the location of interest. Because of age related changes in the hypsodont teeth of the horse, it is beneficial at times to take lesion-orientated oblique views of the infected area and the opposite (normal) side of the skull to have a comparison film to evaluate.

Good quality radiographs can be taken with a high-frequency portable x-ray unit capable of generating 80KVp and 15 MA. Medium or regular speed rare earth cassettes with fast speed film without a grid can be used with a focal film distance of 80-100cm. Most of the DR and CR systems on the equine market

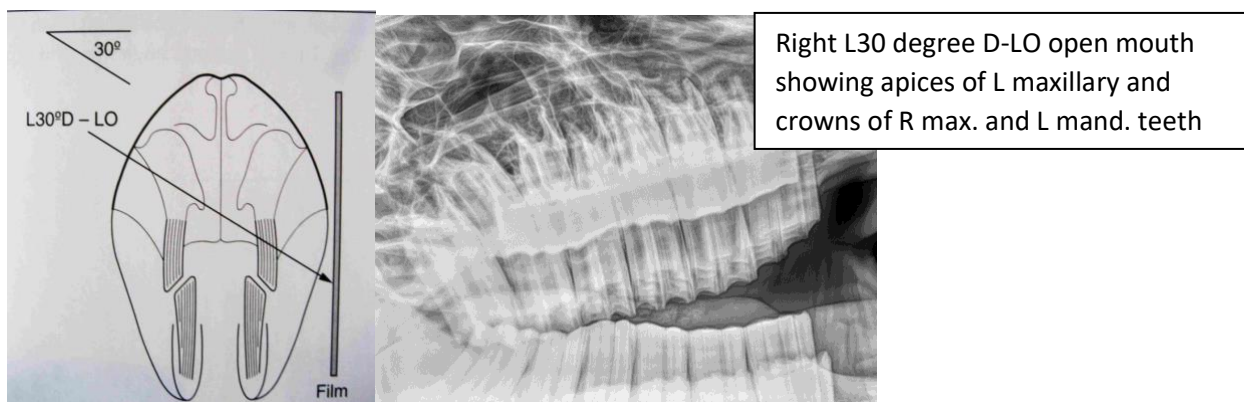
are well suited to head and dental radiography. A table or headstand with a flat surface (approximately 100cm off the ground) is used to support the sedated horse's head. Smaller cassettes are used for lesion oriented oblique films. Wooden or foam blocks are used to position the head and x-ray cassettes. These blocks are also used to support smaller cassettes and to elevate the cassettes to the height of the cheek teeth arcade. Bungee cords are useful to hold cassettes in position. A blindfold or towel placed over the horse's eyes aids in restraint and helps avoid motion artifacts. Sections of PVC pipe or a wooden block can be used as mouth gags. Two sections of 3-meter-long x 0.5cm diameter cotton or nylon rope are used to steady the horse's head and/or put traction on the mandible. A cassette holder and suitable radiation protection equipment consisting of gloves, apron, and thyroid guards are used when taking the x-rays.

Heavy sedation of the horse is necessary both to safely obtain skull radiographs and to facilitate separation of the maxillae and hemi-mandibles. This allows time for a comfortable and detailed oral examination and relaxed, motionless radiographs with the horse resting its muzzle on the table or headstand.

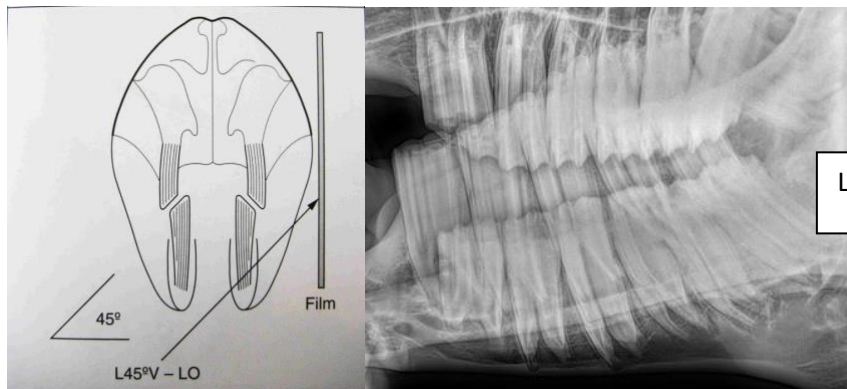
DENTAL RADIOGRAPHS VIEWS AND TECHNIQUE

Lateral Radiograph: This view is obtained with the cassette positioned in a vertical plane, as close as possible to the affected side of the head. The rostral aspect of the facial crest is approximately the center of the cheek tooth rows in most horses, and the horizontal x-ray beam should therefore be centered at this point. This view is easy to obtain and is useful for assessment of the paranasal sinuses for fluid lines, which may be caused by empyema due to apical infection of the 3rd to 6th maxillary cheek teeth. The main disadvantage of this view is that the apices of the left and right cheek teeth are superimposed and it is therefore not possible to evaluate individual apices for radiographic changes.

30-45 degree Dorsolateral-lateral Oblique Radiographs (maxillary cheek teeth apices): This oblique radiographic view separates the left and right maxillary cheek teeth rows, allowing evaluation of individual apices and the surrounding maxilla. The cassette is again positioned in a vertical plane, as close as possible to the affected side of the head. The x-ray tube is positioned at a higher level on the opposite side, with the beam directed 30-45 degrees down from the horizontal and centered at the rostral aspect of the facial crest. The additional presence of rostro-caudal angulation is a common technical fault associated with this projection and should be avoided.

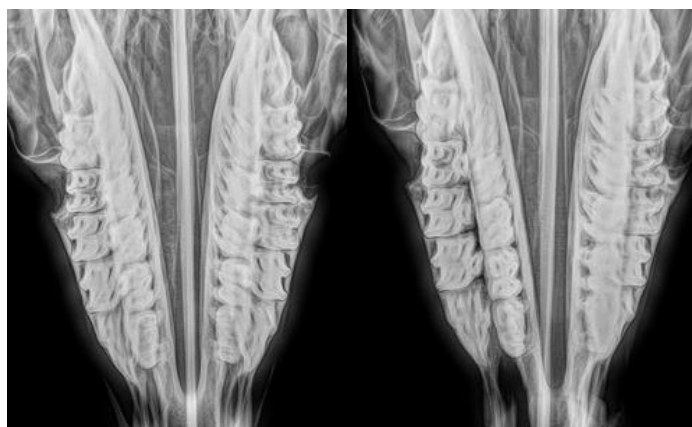


45-60 degree ventrolateral-lateral oblique radiographs (mandibular check teeth apices): This oblique radiographic view separates the left and right mandibular cheek teeth rows, allowing evaluation of individual apices and the surrounding mandible. For this projection, the cassette is again positioned vertically as close as possible to the affected side. The x-ray tube is positioned at a lower level on the opposite side, and the beam directed 45-60 degrees up from the horizontal, centered on the affected tooth. Although increasing the angle gives greater separation of the left and right cheek teeth rows, increasing distortion of the apices also occurs, making dental evaluation more difficult. A larger angle is required to separate the cheek rows in smaller heads where the inter-mandibular distance is short. The thick masseter and pterygoid muscles overlay the caudal 2-3 cheek teeth and increased exposure is usually required to image these apices, as compared to the rostra 3-4 cheek teeth.

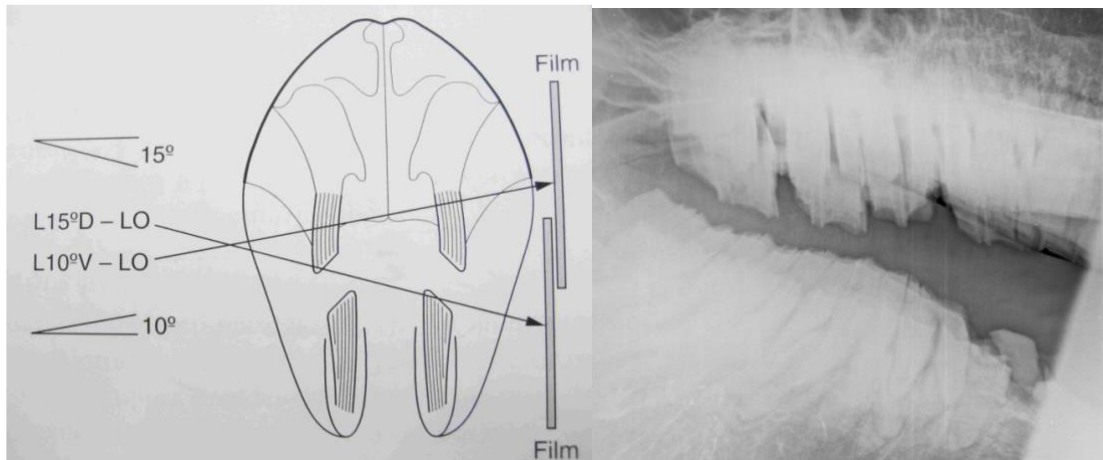


Left L45 degree V-LO open mouth

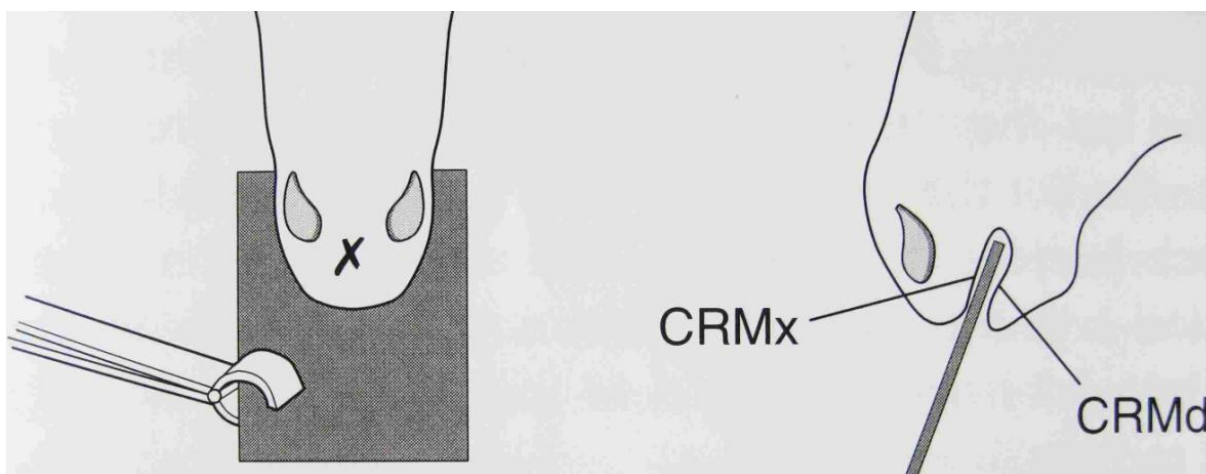
Dorso-ventral Radiographs: This radiographic view is obtained by positioning the cassette underneath and parallel to the hemi-mandibles (the horse's head can be 'rested' on the cassette). The x-ray beam is directed perpendicular to the plate, centered in the midline, at the level of the rostra aspect of the facial crest. Positioning is very important when taking this radiographic view because any lateral distortion from a true DV will cause superimposition of the mandibular and maxillary arcades on one side. This view is most useful for evaluating the areas of the ventral conchal sinus (medial compartment of the rostral maxillary sinus), nasal cavity, and nasal septum. Laterally or medially displaced teeth can also be observed from this view, sagittal fractures, and advanced caries of the maxillary cheek teeth can also be detected. The mandibular cheek teeth are not as easily evaluated from this view because the dense cortical bone of the hemi-mandibles overlies their lateral aspects. Transverse fractures of the mandible and occasionally maxillary bone fractures may also be observed with this view. The lower jaw can be displaced to one side with the mouth open allowing unobstructed viewing of the first 4 upper cheek teeth.

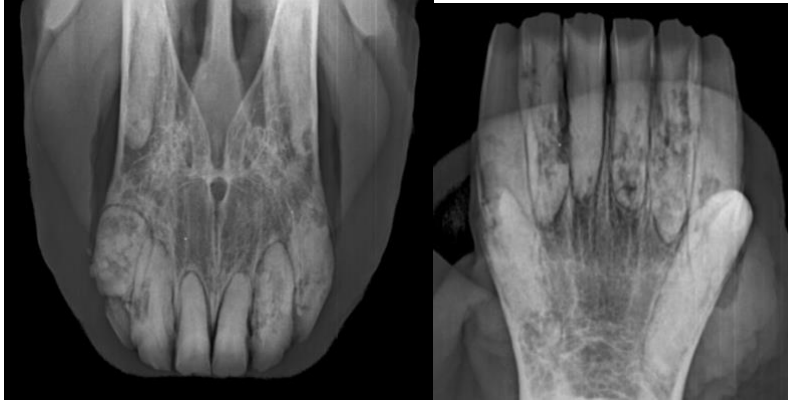


Open-mouthed Oblique Radiographs (15 degrees ventrolateral-lateral for maxillary erupted crowns, 10-15 degree dorsolateral-lateral for mandibular erupted crowns): These radiographic projections are useful for evaluating the erupted (clinical) crown of the cheek teeth, which are usually not visible on conventional views due to superimposition of the opposing arcade. A Butler's gag, PVC pipe or wooden block is placed between the incisors of the sedated patient to separate the maxillary and mandibular erupted crowns. The direction of the x-ray beam is the opposite of that used for conventional views and the angle of incidence of the beam is also reduced (i.e., 10-15 degrees). Disorders such as coronal fractures, diastemata and disorders of wear can be well evaluated using these projections. Steeper angle views with the mouth wide open can be used to evaluate reserve crowns and even palatal roots in older horses.

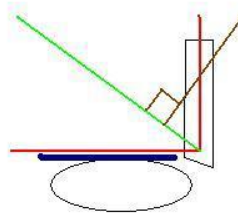
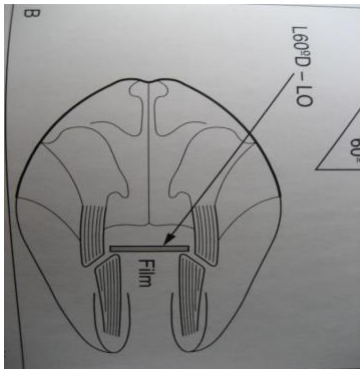


Intra-oral Occlusal Radiographs of Incisor Teeth: These projections are useful for evaluating the incisors and canines. A small cassette or non-screened film is placed between the incisors and canines, as far caudally as possible, and the x-ray beam is directed at 60-80 degrees to include the reserve crown and apices of the incisors.

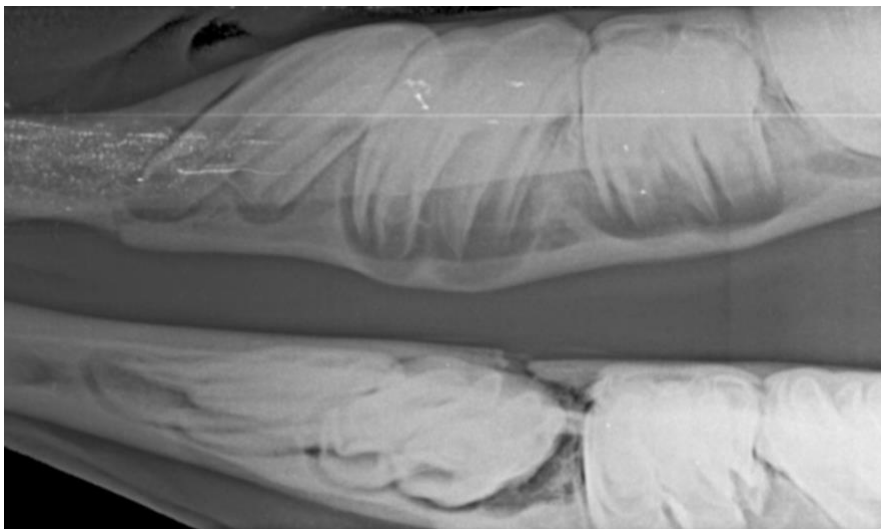




Intra-oral Radiographs of the Check Teeth: This modified Gibbs technique utilizes a flexible 4"x 8" cassette and a bisecting angle technique that was perfected by Dr. David Klugh. It provides evaluation of a single tooth from crown to apex. The horse is sedated and a full mouth speculum is used to hold the mouth open. The flexible cassette and film are introduced into the mouth and placed against the teeth to be evaluated. The x-ray beam is directed at a bisecting angle to the teeth and cassette to minimize image distortion. High quality images of several teeth in a single arcade can be obtained with this technique without superimposition of the opposite arcade.



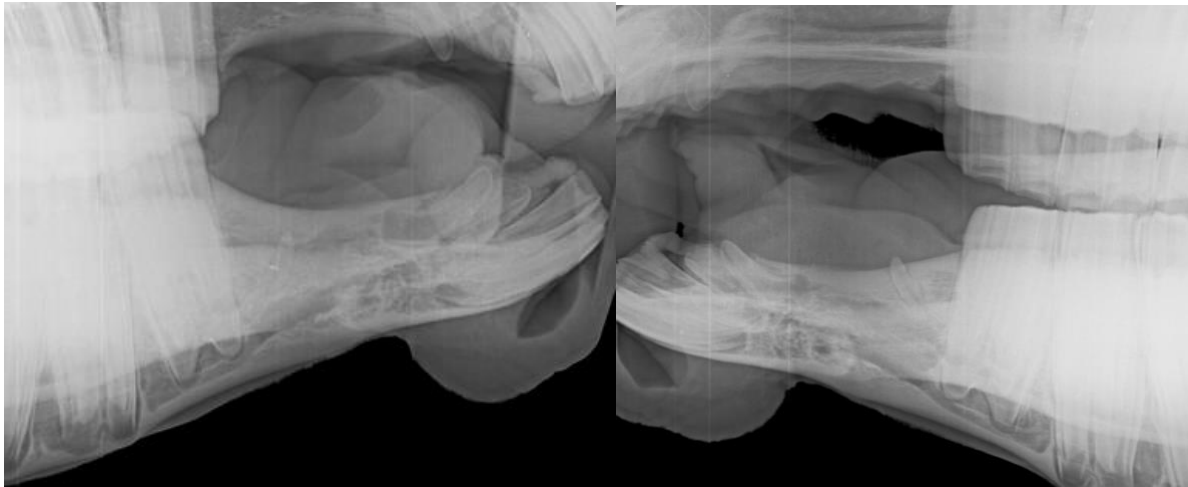
The blue line is the film the brown line is the generator beam.



Mandibular fracture could only be detected on intraoral V-D views.

Additional Radiographic Techniques: The use of a small metal marker (e.g., paper clip or skin staple) placed over an area of maximal facial swelling can be useful when evaluating radiographic changes suspected to involve the cheek teeth apices, and to assess their likely significance. If an external sinus tract is present, a blunt, malleable metallic probe should be inserted into the tract and the appropriate lateral oblique radiograph taken. This procedure can provide irrefutable evidence of dental disease, identify the affected apical area of the tooth, and provide a landmark for placement and angulation of the dental punch if tooth repulsion is to be performed. Lateral oblique radiographs often have a degree of rostro-caudal distortion; the horse lowering its head when sedated can cause this. Consequently, if the relationship of the angle of the probe to the angle of the tooth is not clear, a true lateral projection should also be obtained with the probe in situ. The injection of contrast material (e.g., Iohexol (Omnipaque)) into a draining tract can similarly provide valuable diagnostic and spatial information.

Radiography of canine and wolf teeth is particularly useful if these structures are unerupted, displaced and/or abnormally angulated, or to provide information to the surgeon prior to attempting extraction. These views should be taken with the affected side next to the cassette and the x-ray beam angled at 10-15 degrees dorsolateral-lateral (to view the maxillary teeth) to separate the teeth on the right and left sides.



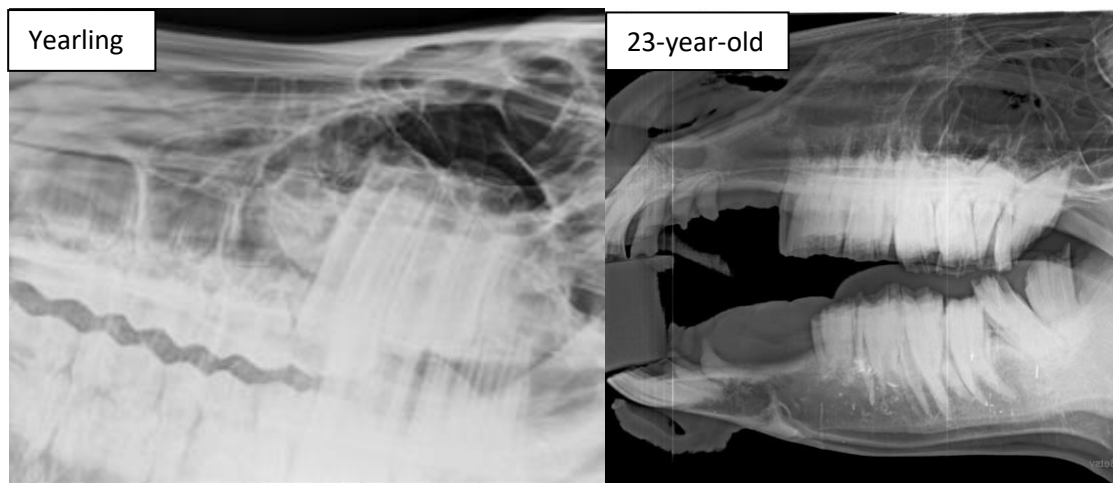Normal Appearance and Age-related Variation in Radiographic Appearance:

The radiographic appearance of the equine cheek teeth, and particularly their apices, varies markedly with age and an appreciation of the normal variations is required to enable proper interpretation of dental radiographs. Most apical infections occur in young horses when there can be marked differences in the appearance of the apical areas of the different cheek teeth. Although radiograph is a very specific diagnostic aid (95% specificity), it is not very sensitive (50% sensitivity), (Gibbs and Lane, 1987 and Weller et al, 2001). Therefore, in early cases of periapical cheek tooth infection, even experienced clinicians may not be able to definitively identify lesions.

Enamel is the densest material in the body. Therefore, the cheek teeth appear as strongly radiodense structures, within which the more radiolucent pulp cavities may be seen running longitudinally. The reserve crown of the cheek tooth is attached to the alveolar bone by the periodontal ligament. The periodontal ligament is evident radiographically as a narrow parallel radiodense rim of cortical bone, the lamina dura denta, which lines the alveolus. Although disruption of this structure is a sign of dental disease, the irregular contour of equine cheek teeth often hides the lamina dura denta of normal teeth.

The area of the periodontal ligament may widen due to disease processes, but young horses with eruption cysts may also have slightly wider radiolucent areas adjacent to the lamina dura denta in the area of the eruption cysts.

Foals are born with 3 deciduous teeth in each row and these may be identified by their short, spiculate roots. The dental sacs in the young horses are large, rounded radiolucent structures with a striated pattern which is due to partially calcified enamel formation. As the dental sacs develop into cheek teeth, their apical areas appear as round, radiolucent areas with a wide periodontal space (eruption cysts). The lamina dura denta is often not visible in the apices of the developing teeth. As the horse ages and the cheek teeth erupt, the true roots (i.e., enamel-free areas) develop and the apices change from rounded to pointed. Bearing in mind that the equine cheek teeth erupt between 1 and 4 years of age, it is a normal feature of young horses to have cheek teeth with variably appearing apical areas. For example, major differences are present between the apices of the third and fourth cheek teeth in a 4-year-old, because the 4th cheek tooth is 3 years older than the 3rd. Consequently, caution must be exercised when comparing the radiographic appearances of adjacent cheek teeth apices in younger horses.



References and Suggested Reading:

Ingren CM, Townsend NB. The use of radiography for diagnosis of apical infection of equine cheek teeth Equine vet. Educ/AE. (2016), 448-454

Barrett M, Park R. Review of Radiographic Technique of the Equine Skull. In: AAEP Proceedings, Vol 57, 2011

Barakzai SZ. Dental Imaging. In Easley J, Dixon PM, Schumacher J, eds Equine Dentistry 3rd ed, Edinburgh: Saunders/Elsevier, 199-230, 2010

Henry T. Equine Dental Films: How to Obtain and Interpret. In: Proceedings of AAEP Resort Symposium, 2016

Barrett MF, Easley JT, Acquisition and Interpretation of Radiographs of the Equine Skull. Equine Vet Educ (2013) 25 (12) 643-652

